

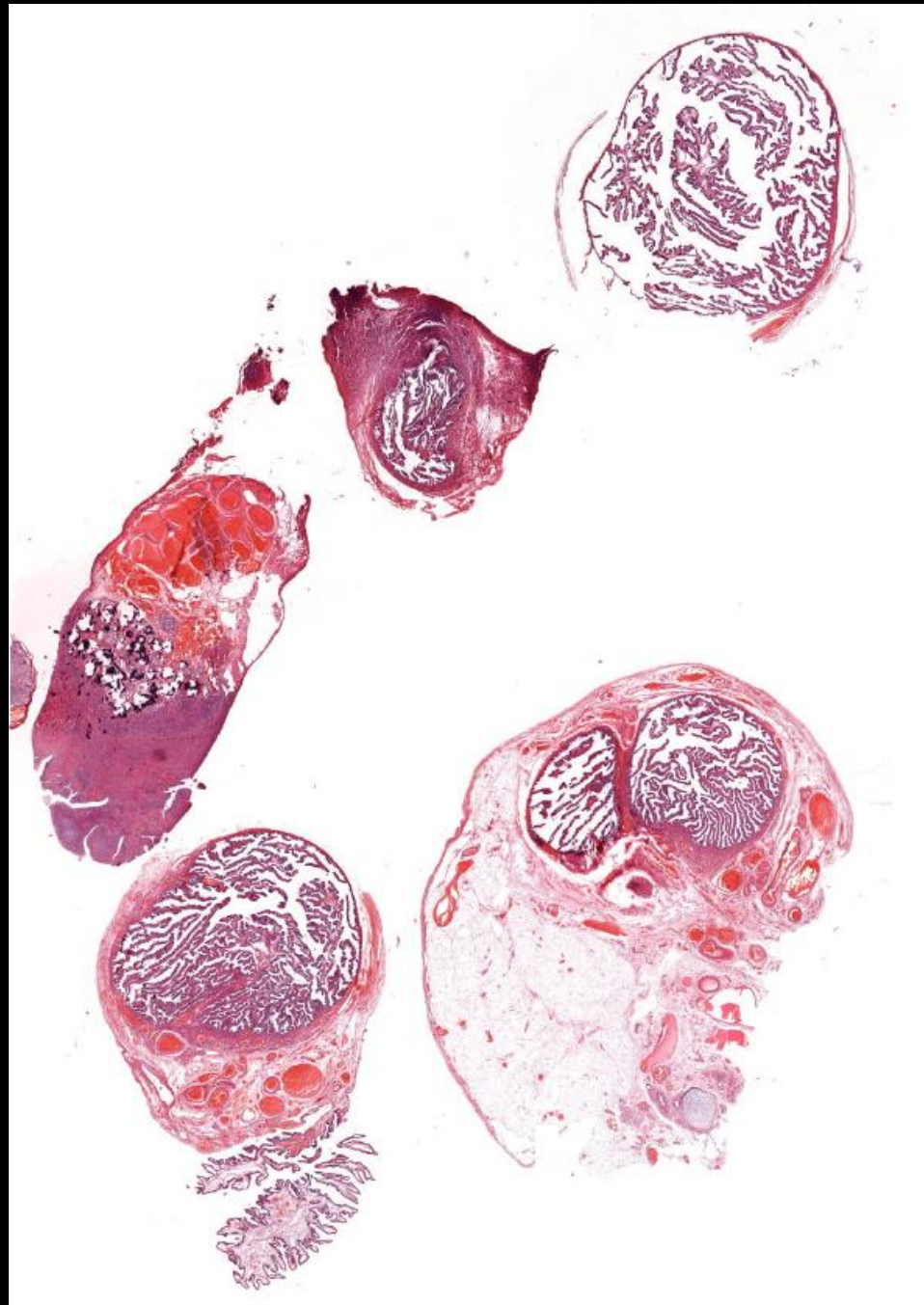
V súvislosti s týmto podujatím  
nemám žiaden konflikt záujmov.

# Prípád SD-IAP č. 724

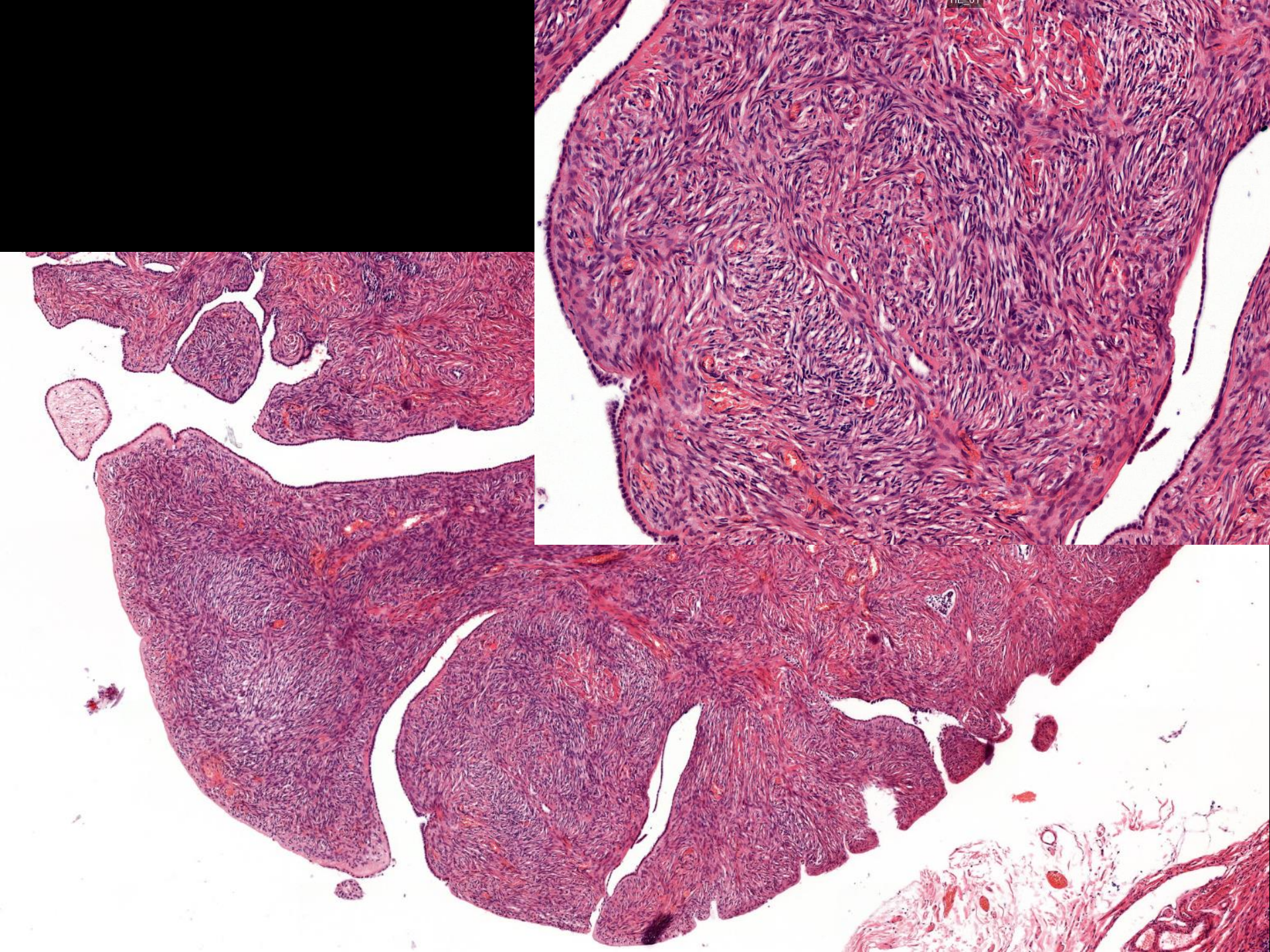
B. Rychlý, Alpha Medical, Bratislava

# Klinické údaje

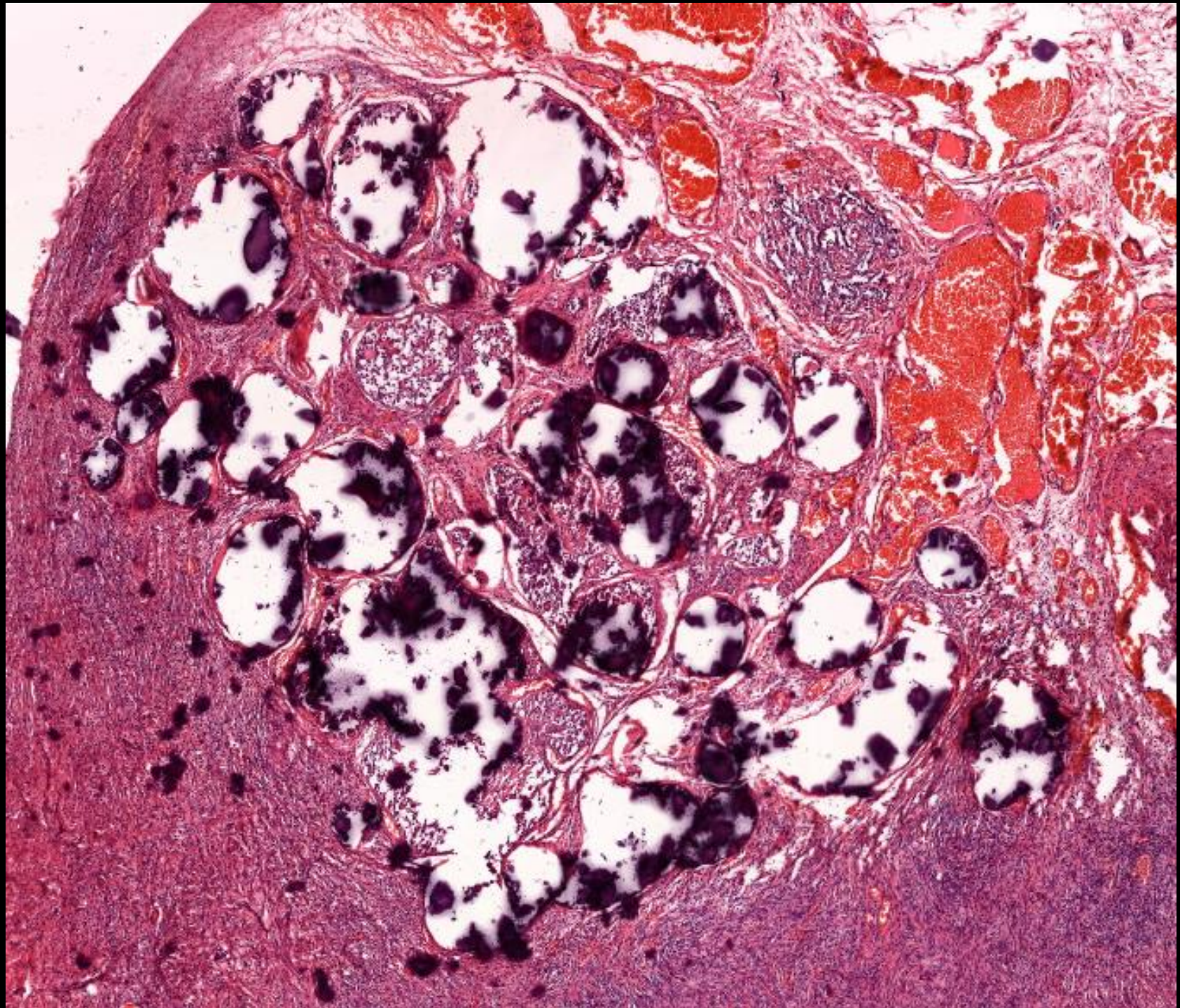
- 18-ročná žena (fenotypicky)
- vyšetrovaná pre primárnu amenoreu
- mierne zvýšený gonádotropný hormón
- sonograficky znázornený hypoplastický uterus a vaječníky (streak)
- karyotyp 46XY, kompletná gonadálna dysgenéza (Swyer syndróm)
- pre riziko gonadálneho tumoru odstránené obe adnexá



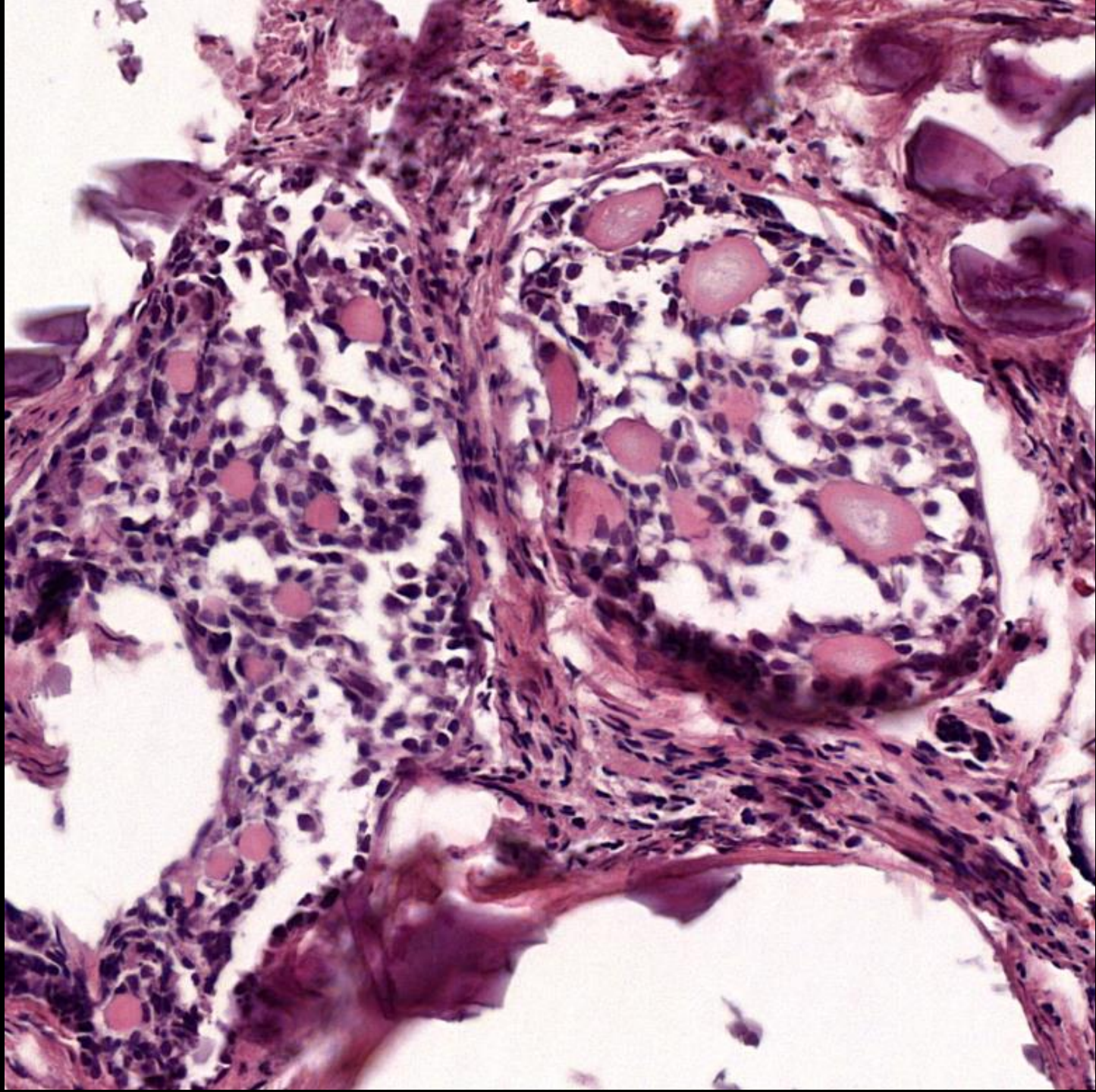




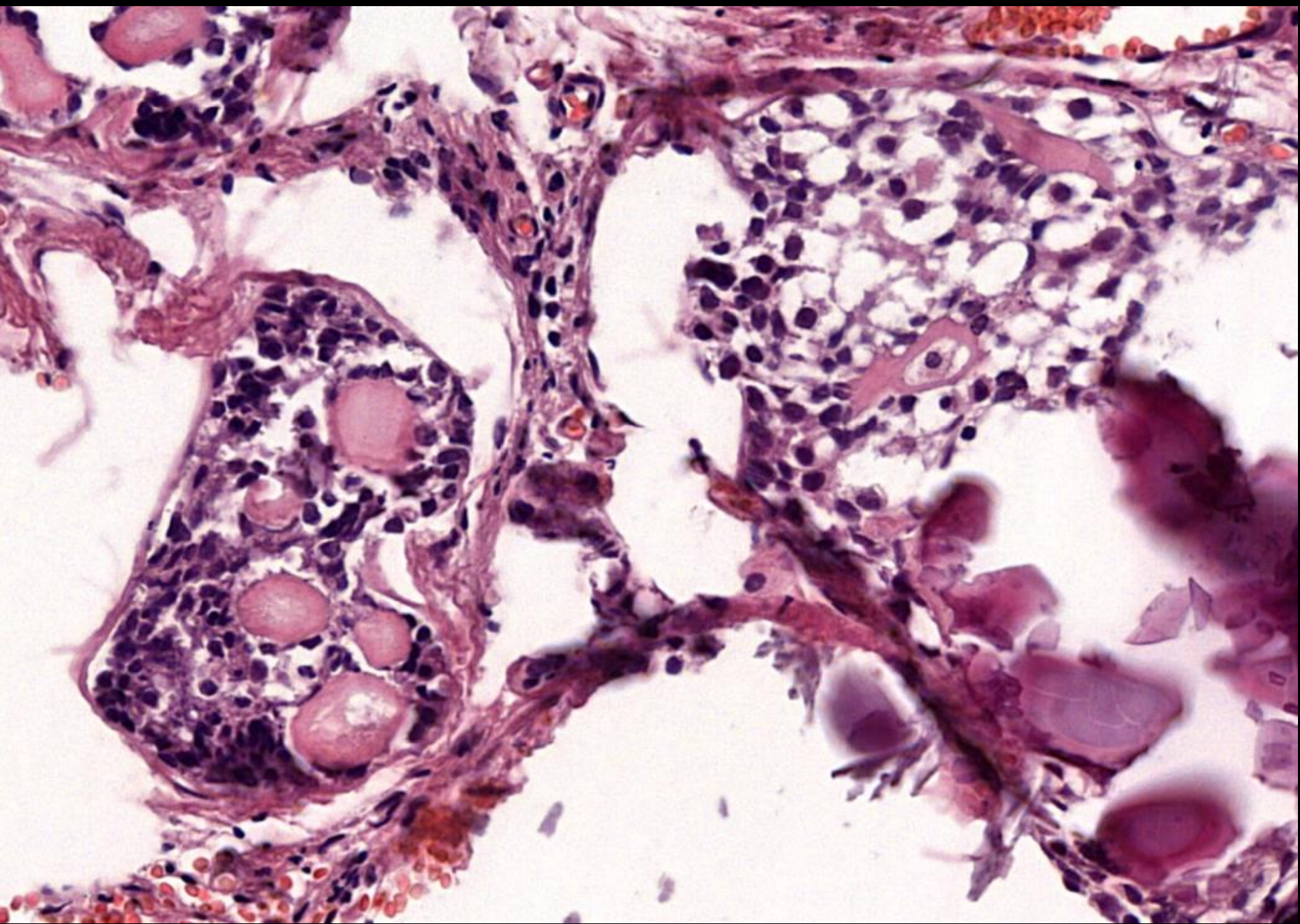




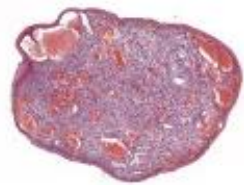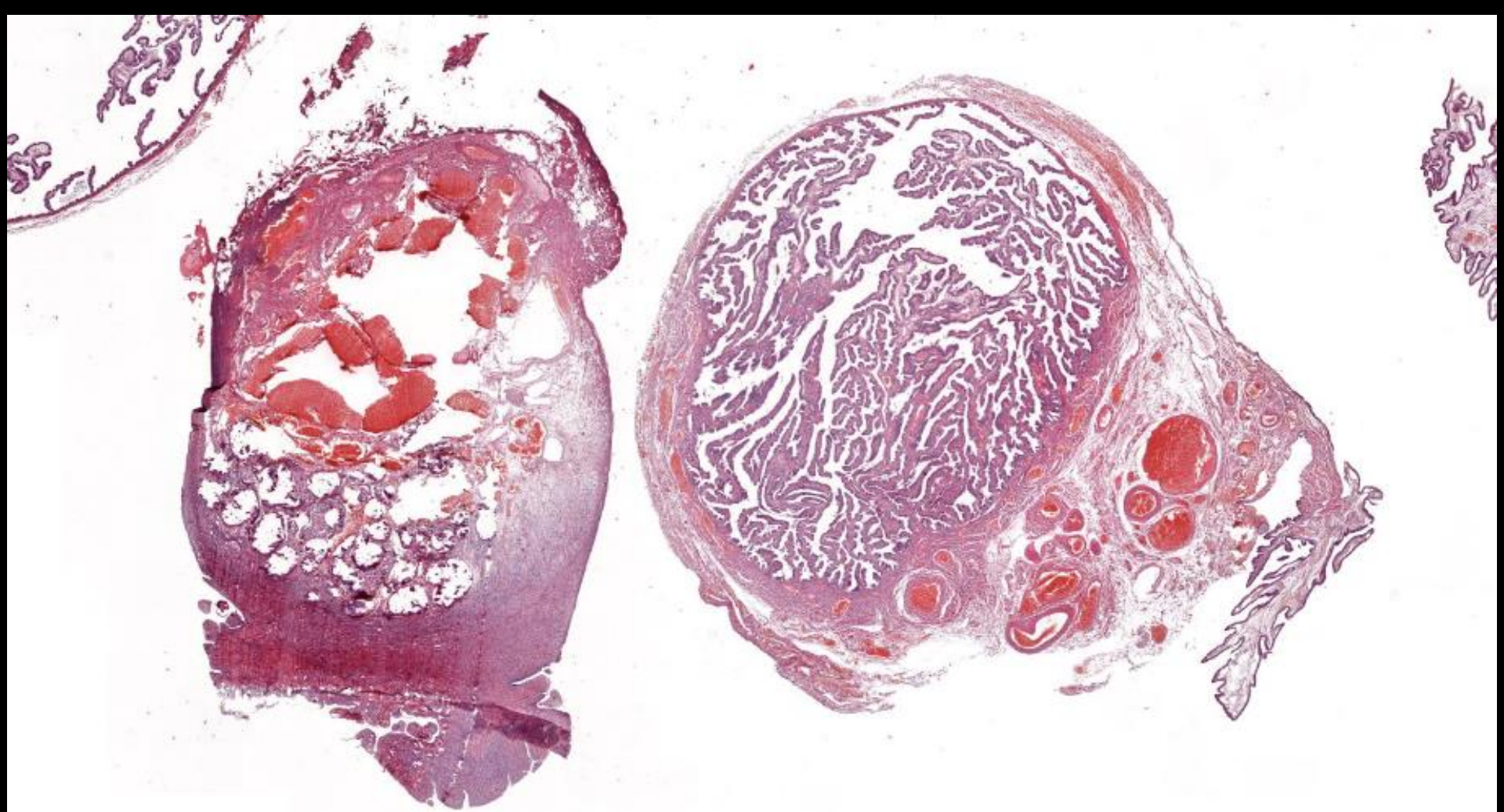






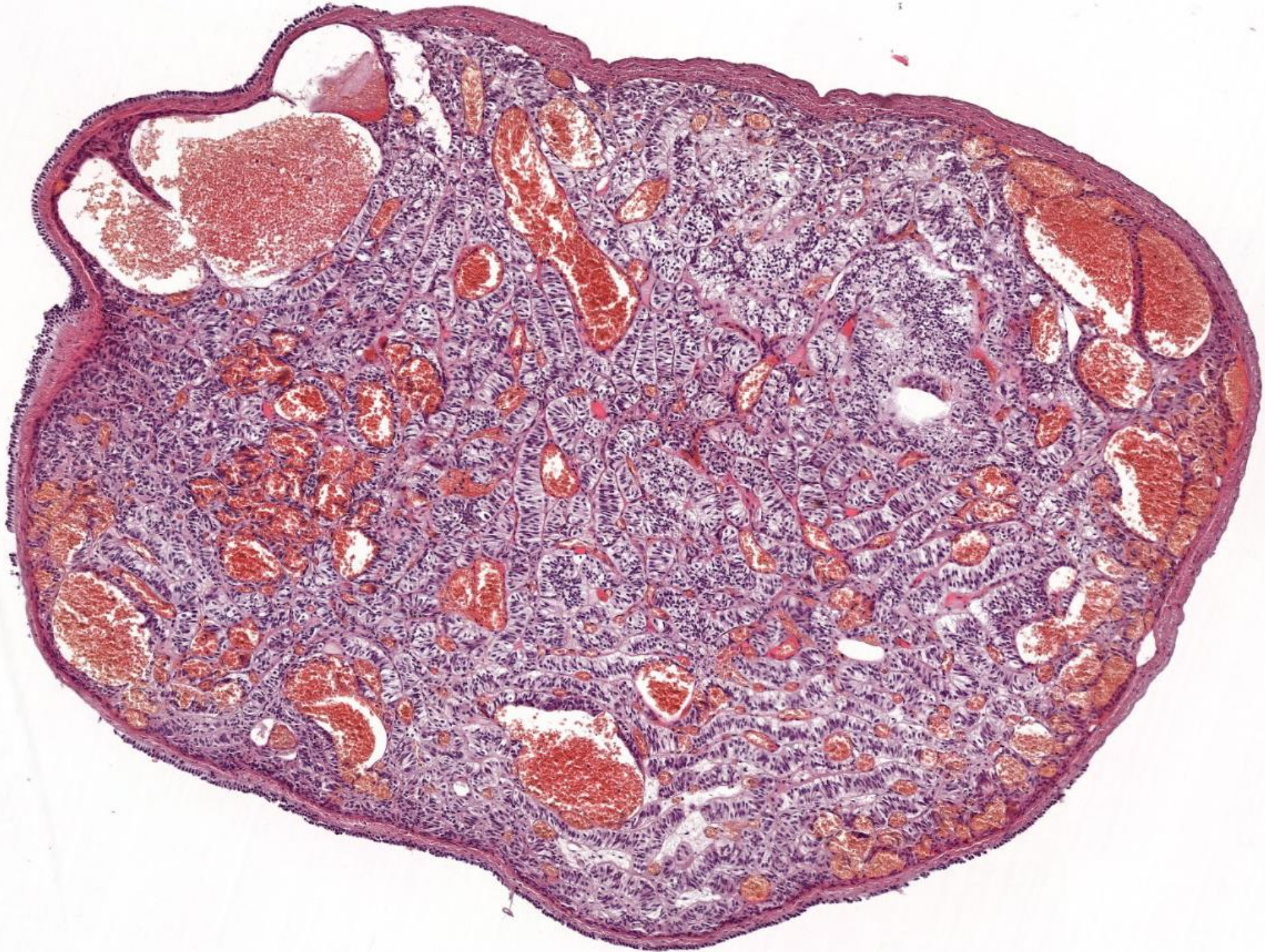




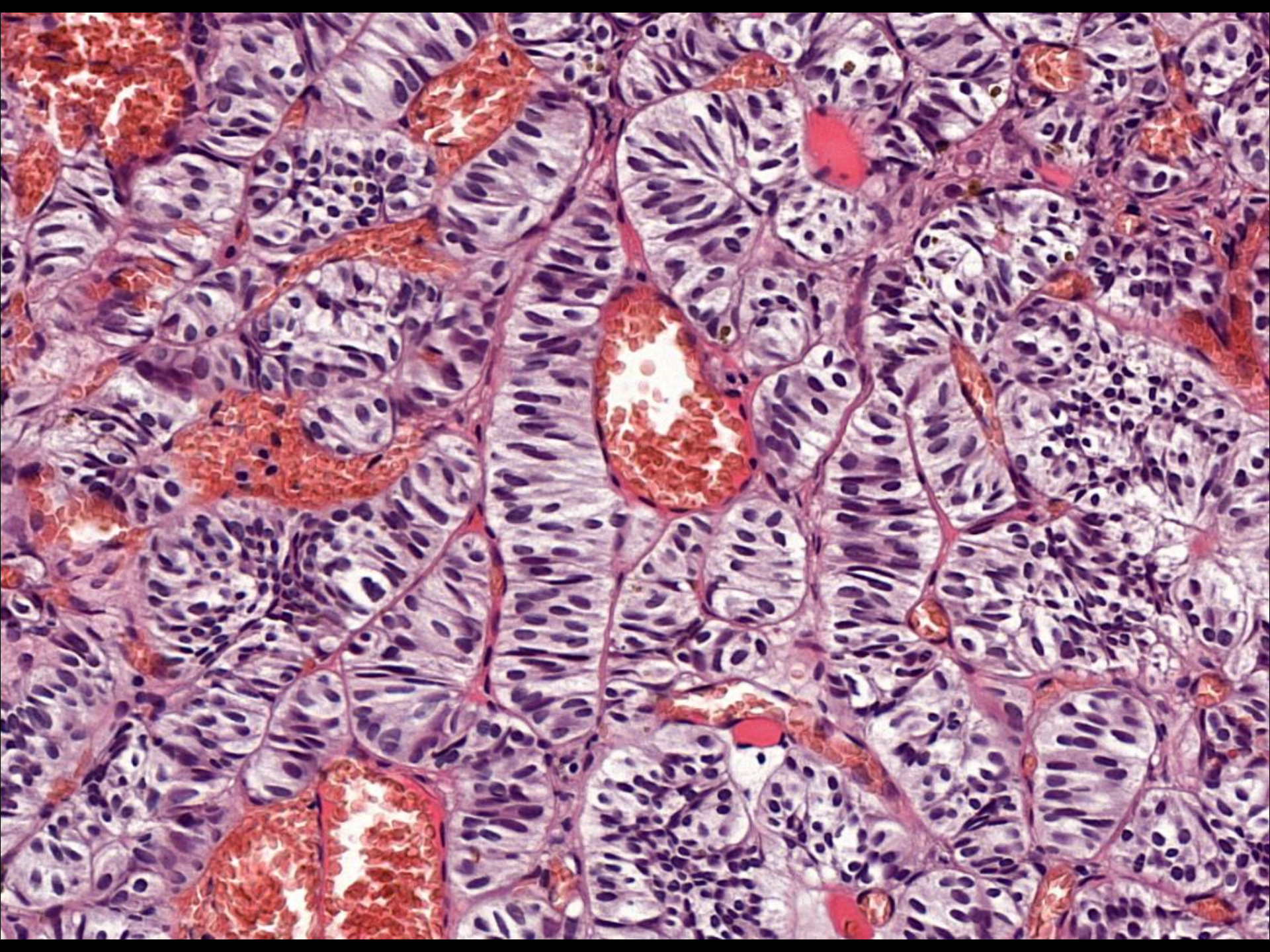


**???**







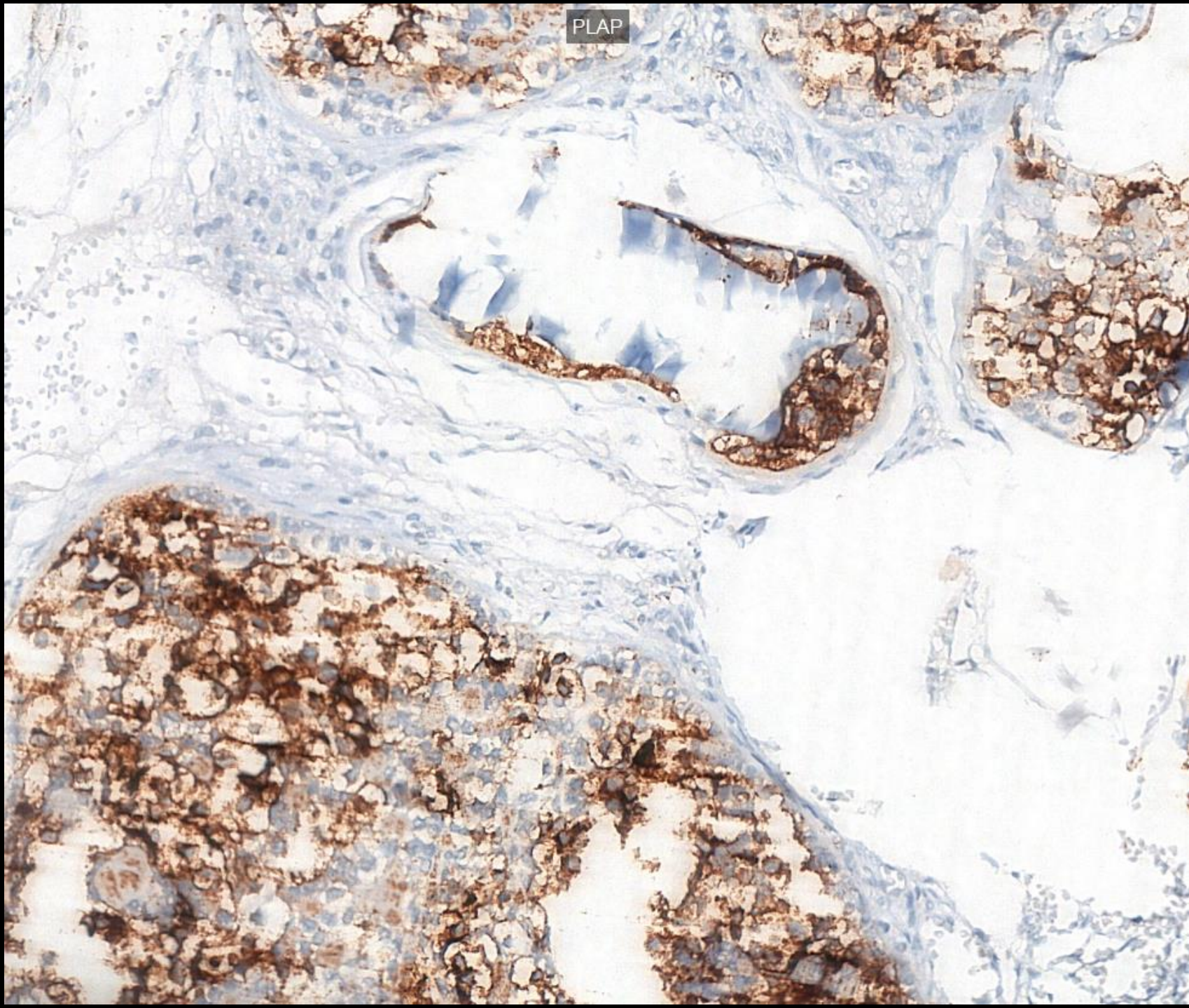




???

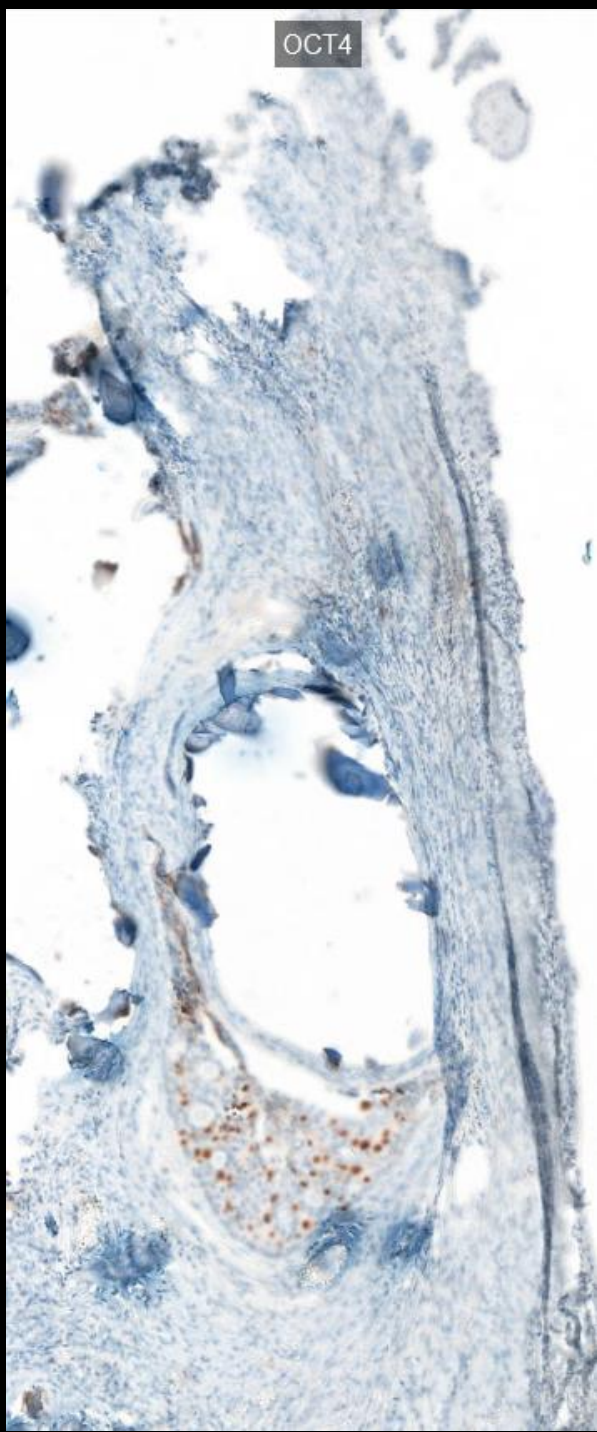


PLAP

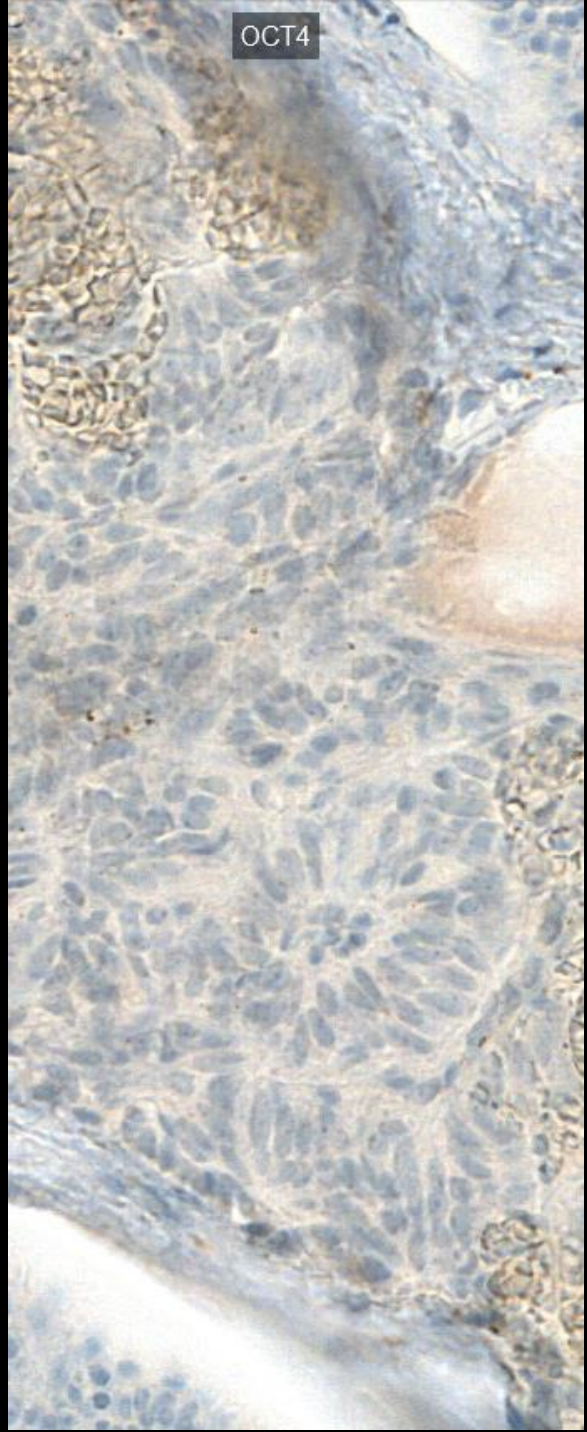




OCT4

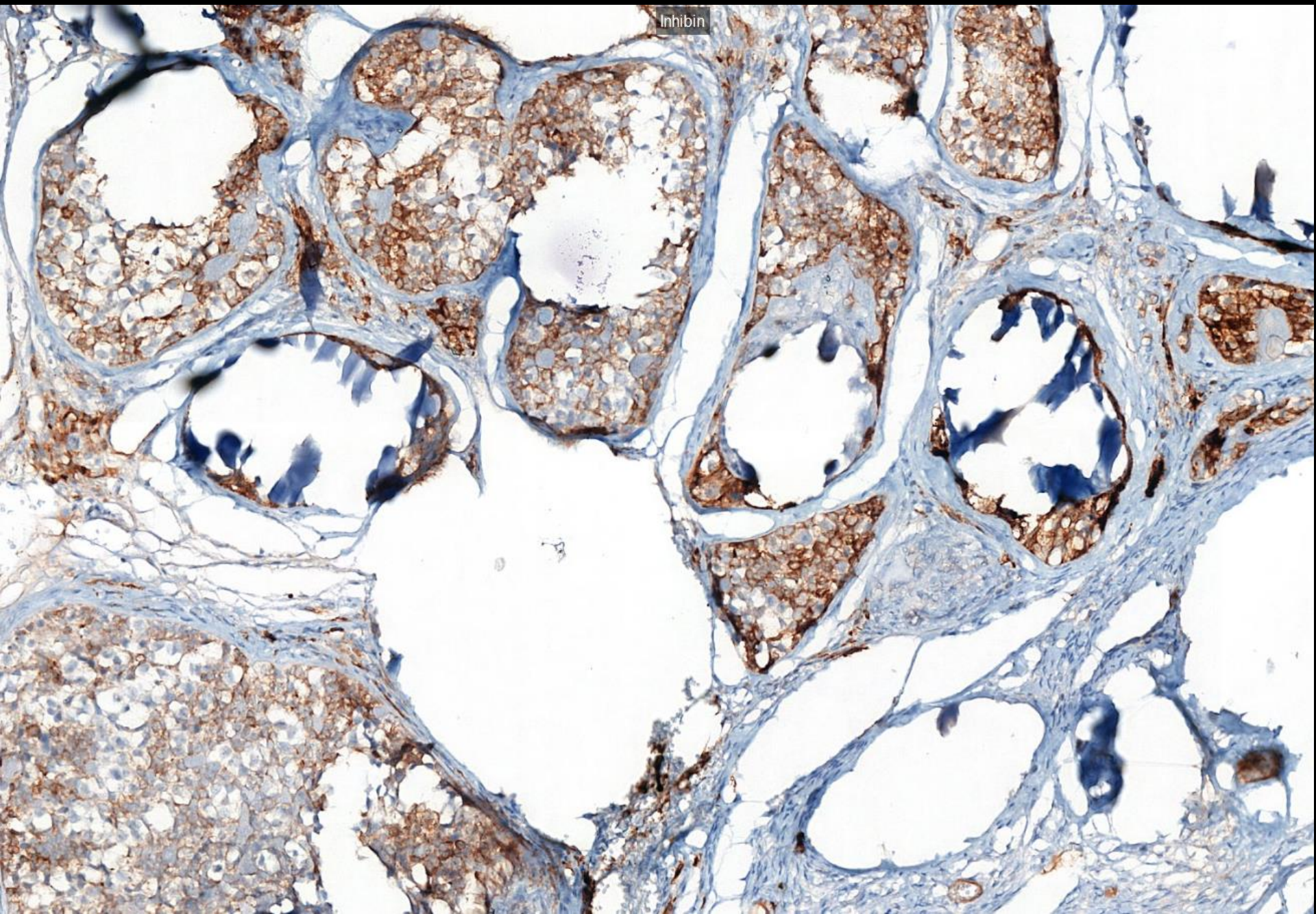


OCT4



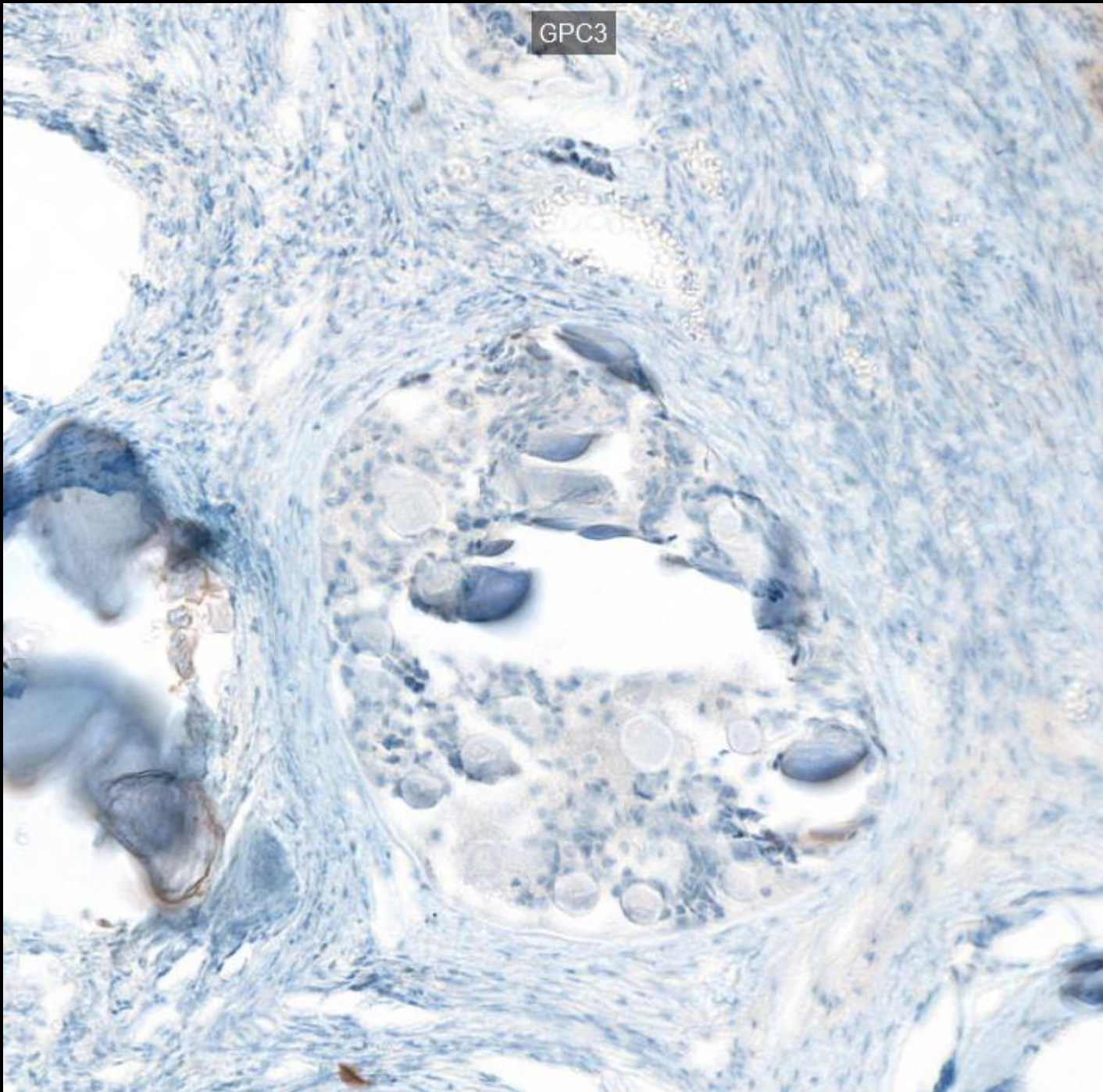


Inhibin

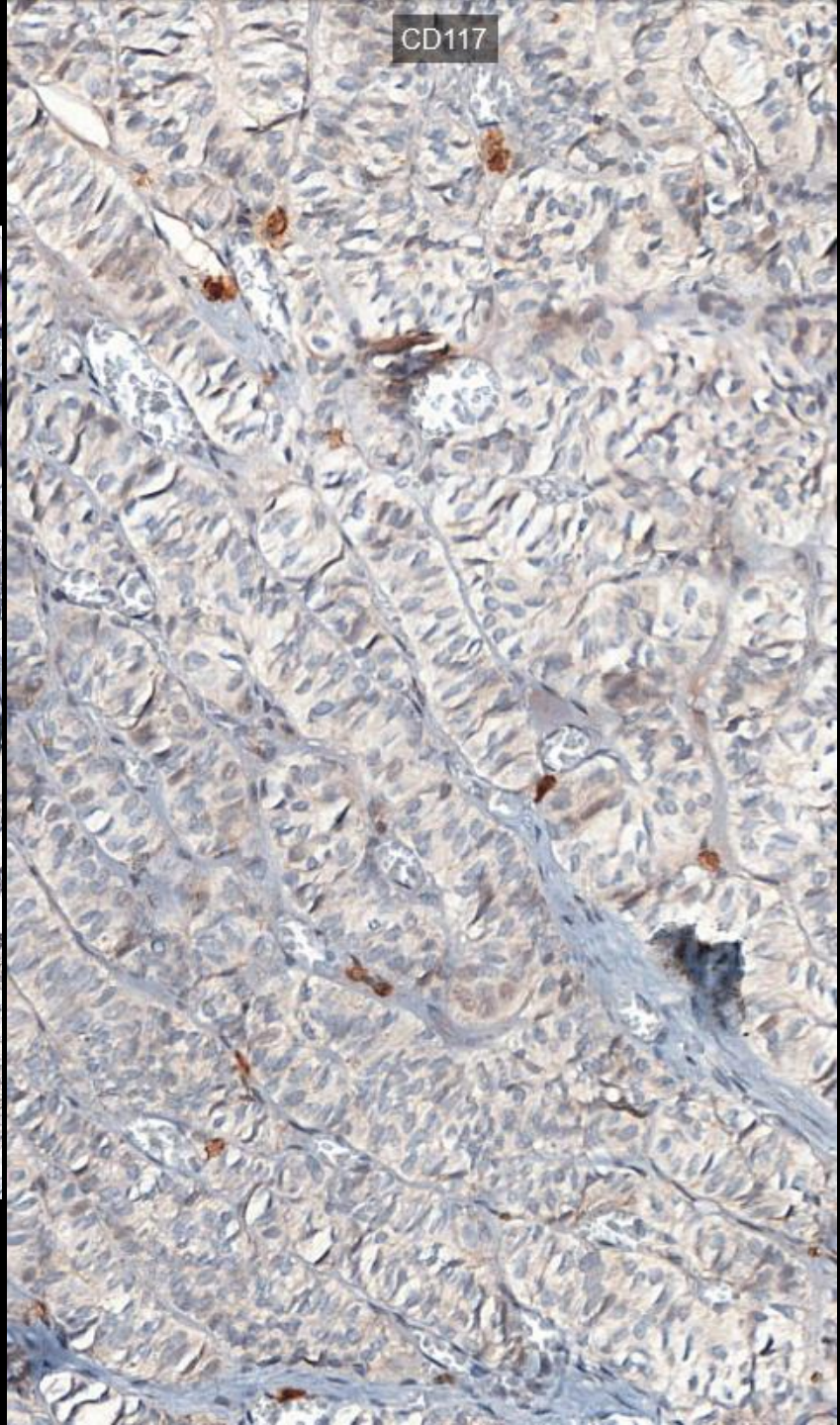
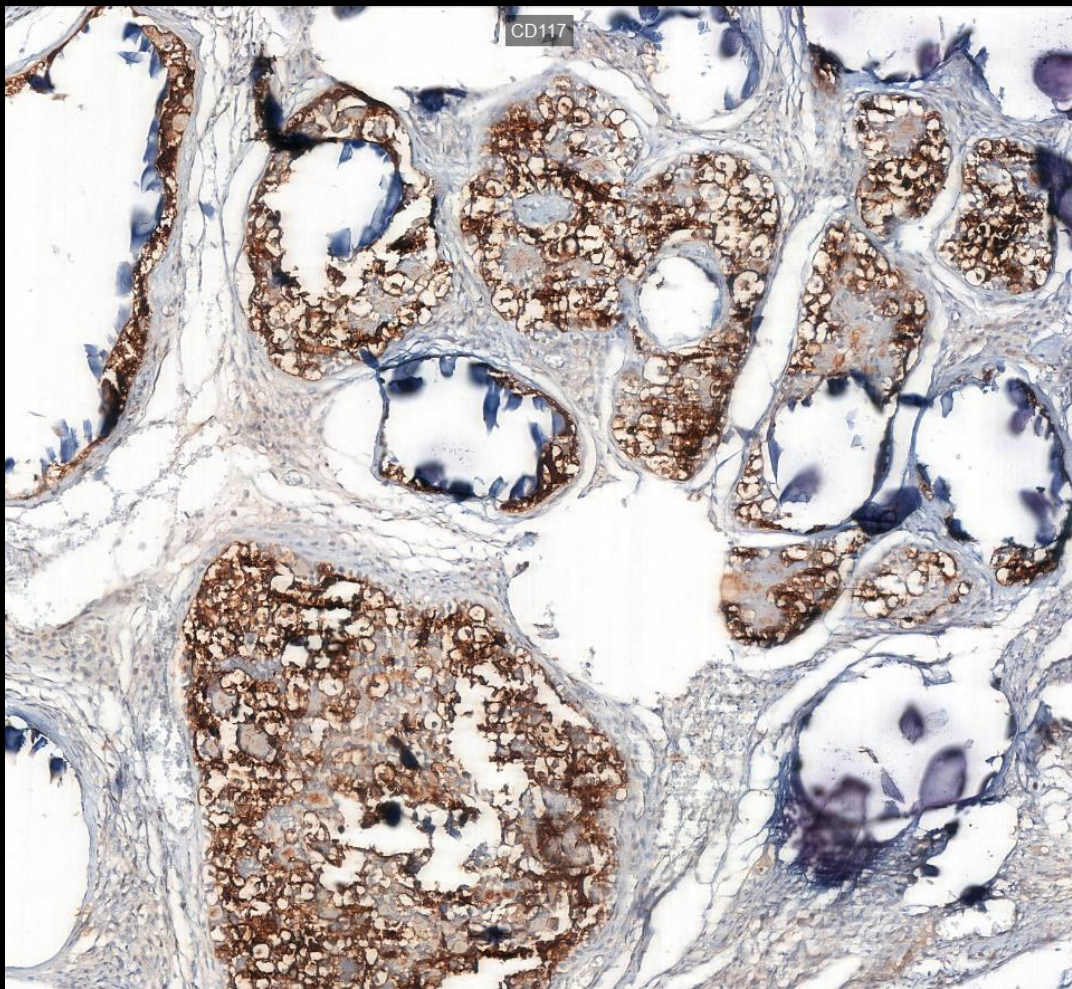




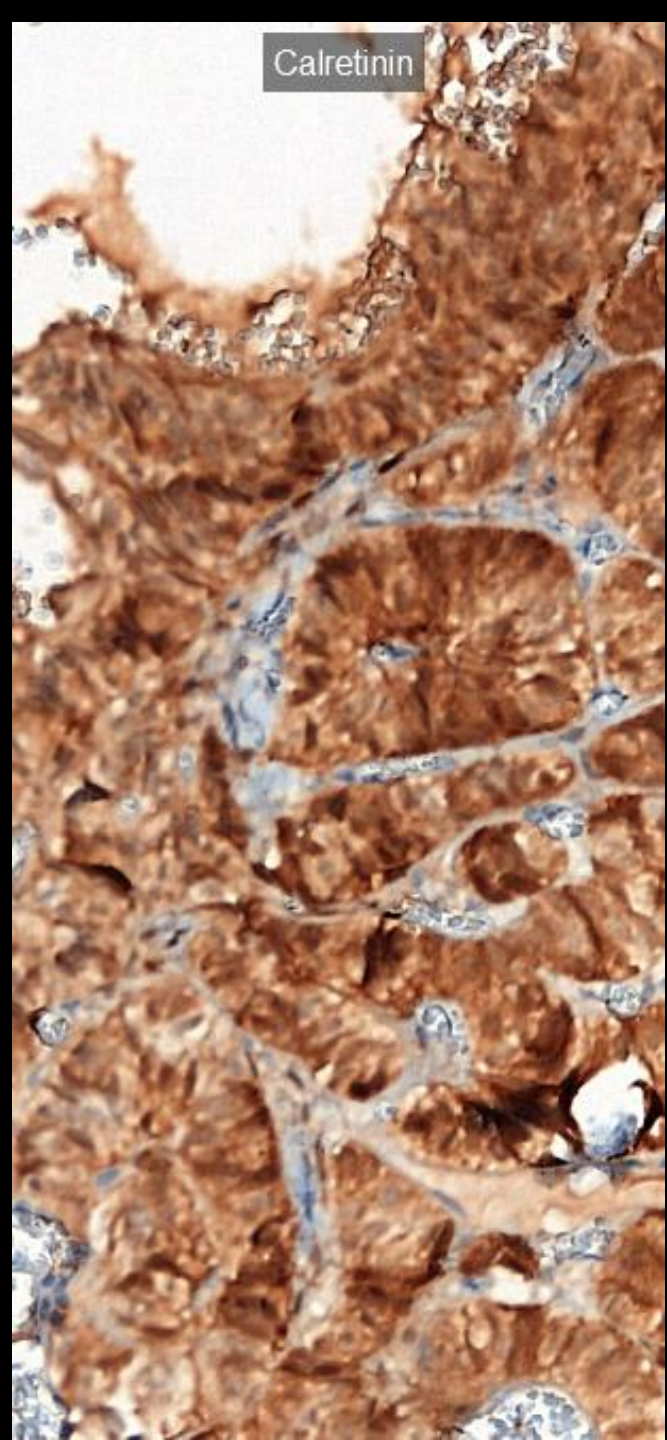
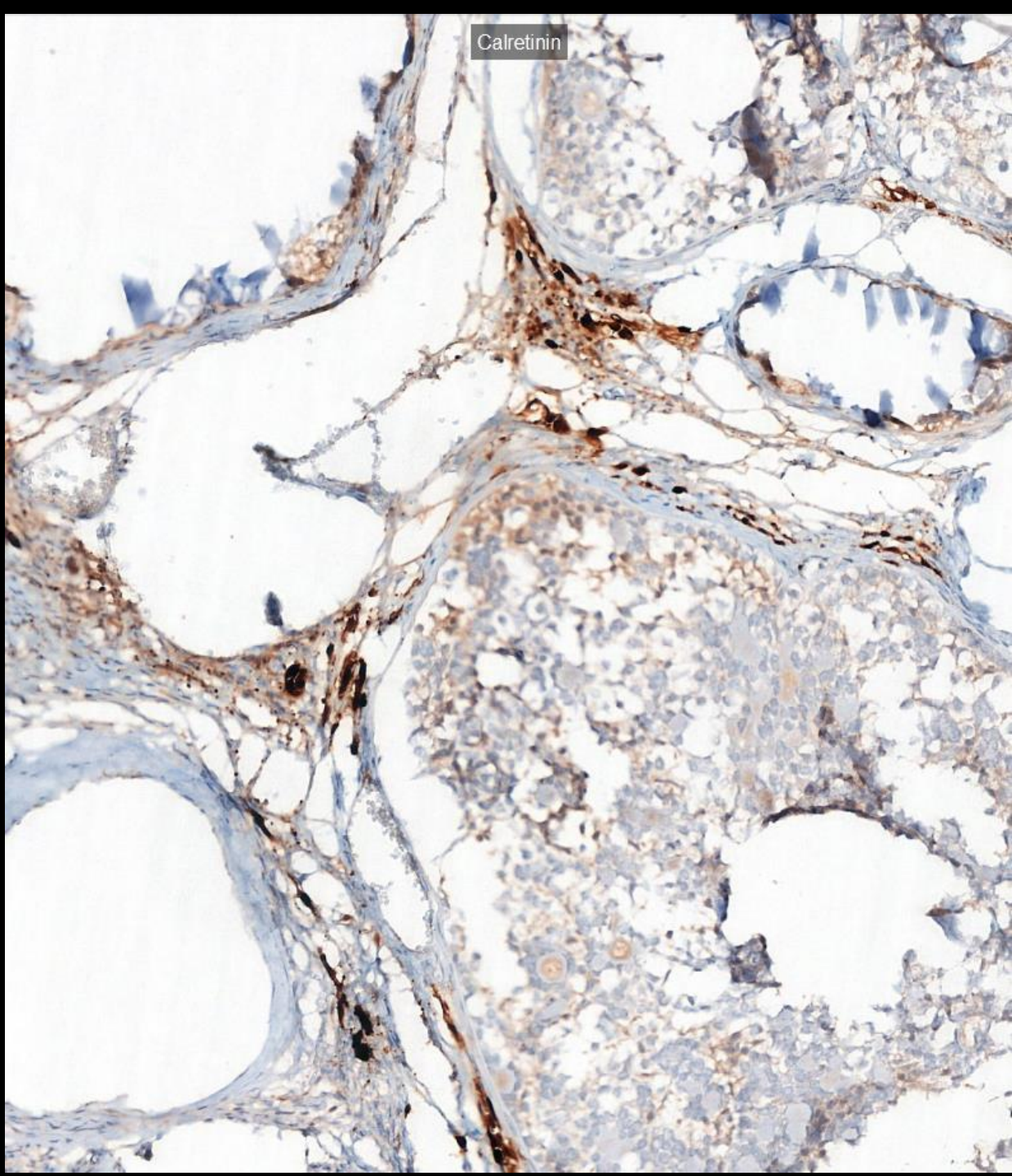
GPC3













???

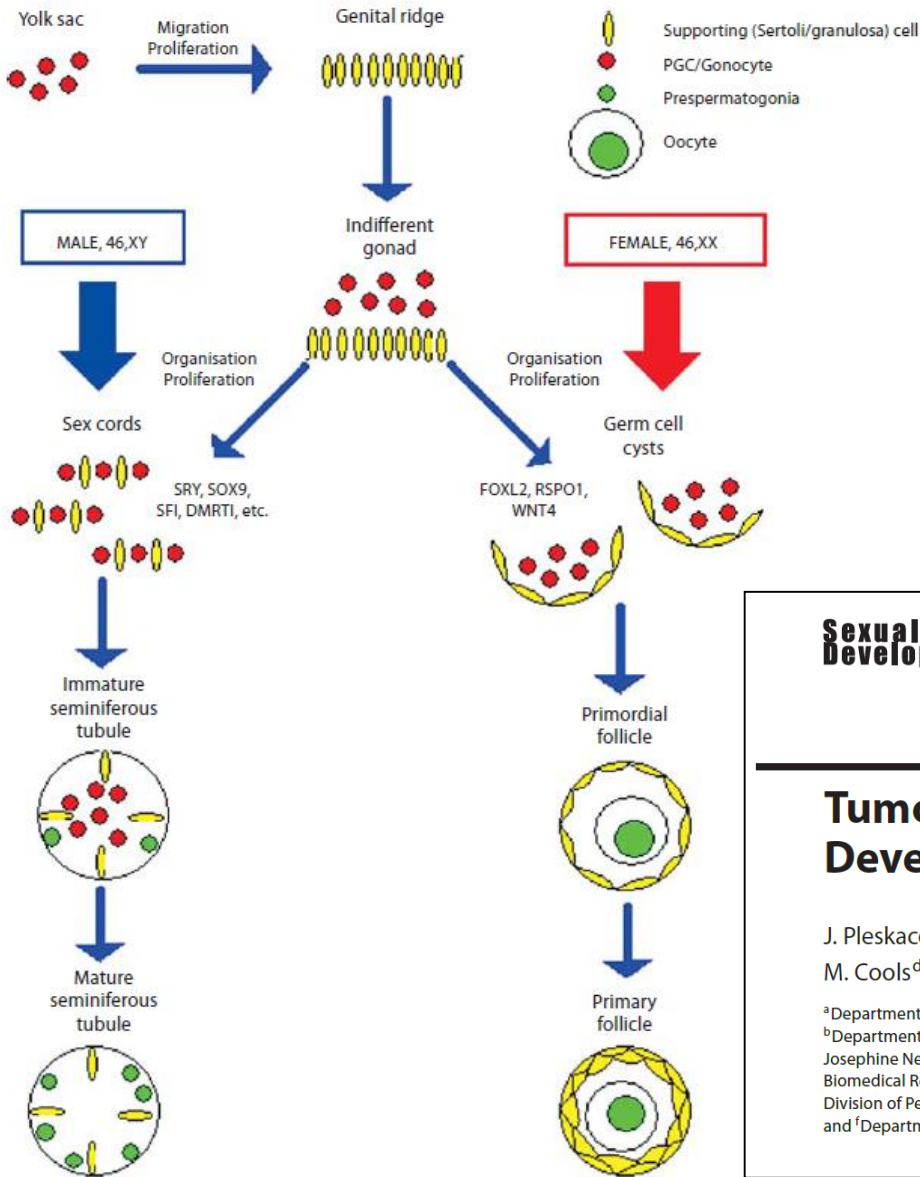


# Diagnóza

Gonádoblastóm

pri kompletnej gonadálnej dysgenéze  
46, XY (Swyer syndróm)





- v 8. týždni
- sex-determining region Y (SRY) gén - proteín
- inaktivačná mutácia SRY génu

## Sexual Development

Sex Dev 2010;4:259–269  
DOI: [10.1159/000314536](https://doi.org/10.1159/000314536)

Published online: June 17, 2010

## Tumor Risk in Disorders of Sex Development

J. Pleskacova<sup>a</sup> R. Hersmus<sup>b</sup> J.W. Oosterhuis<sup>b</sup> B.A. Setyawati<sup>c</sup> S.M. Faradz<sup>c</sup>  
M. Cools<sup>d</sup> K.P. Wolfenbuttel<sup>e</sup> J. Lebl<sup>a</sup> S.L. Drop<sup>f</sup> L.H. Looijenga<sup>b</sup>

<sup>a</sup>Department of Pediatrics, Charles University, 2nd Faculty of Medicine, Prague, Czech Republic;

<sup>b</sup>Department of Pathology, Erasmus MC-University Medical Center Rotterdam, Daniel den Hoed Cancer Center, Josephine Nefkens Institute, Rotterdam, The Netherlands;

<sup>c</sup>Department of Human Genetics, Center for Biomedical Research, Faculty of Medicine, Diponegoro University, Semarang, Indonesia;

<sup>d</sup>Department of Pediatrics, Division of Pediatric Endocrinology, University Hospital Ghent, Ghent, Belgium;

<sup>e</sup>Department of Pediatric Urology and

<sup>f</sup>Department of Pediatric Endocrinology, Erasmus MC-Sophia Children's Hospital, Rotterdam, The Netherlands



# Swyer syndróm

- kompletná gonadálna dysgenéza
- fenotypicky ženy
- 46 XY karyotyp (ženský pseudohermafroditizmus)
- primárna amenorea
- hypoplastický uterus, normálne tuby, „streak“ gonády
- vysoké FSH



# Swyer syndróm

- vysoké riziko germinálnych nádorov, 30% (v čase dg. / puberta), kumulatívne s vekom, 80% vo veku 40 rokov
- profylaktická obojstranná gonadektómia (cca 35 % je obojstranných)



# Gonádoblastóm a TSPY1

- TSPY1 (testis specific protein Y-encoded)
- proteín v semenníkoch s úlohou v spermatogenéze
- TSPY1 = gonadoblastoma locus na Y chromosome (jediný známy onkogén na Y chromozóme)



# Gonádoblastóm

- dysgenetická gonáda
- nediferencované gonadálne tkanivo  
(syn. disekujúci gonádoblastóm?)
- mutácia TSPY1 – gonádoblastóm
- čistý gonádoblastóm nemetastázuje  
(in situ germ cell neoplázia)

# Gonádoblastóm

- regresia (burn out) alebo ďalšie aberácie (izochromozóm 12p) – progresia (50 %) do invazívneho germ cell tumoru
- najčastejšie dysgerminóm
- yolk sac, embryonálny karcinóm, choriokarcinóm, teratóm

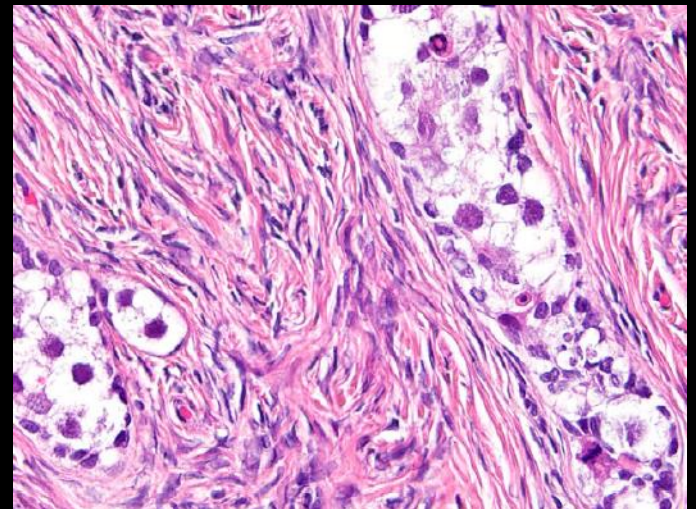


# Gonádoblastóm

- prakticky výlučne u jedincov s kompletnou gonadálnou dysgenézou s prítomnosťou Y chromozómu alebo jeho časti

# Prekurzorová lézia gonádoblastómu

- nediferencované gonadálne tkanivo (disekujúci gonádoblastóm)
- dominancia gonadálnej strómy





# Gravidita?

## Pregnancy in patient with Swyer syndrome

*Ivan Tulic, M.D., Ph.D., Lidija Tulic, M.D., and Jelena Micic, M.D.*

Gynecology and Obstetrics Institute, Clinical Center of Serbia, School of Medicine, University of Belgrade, Belgrade, Republic of Serbia

**Objective:** To report a case of successful pregnancy and delivery after IVF and ET in a patient with Swyer syndrome.

**Design:** Case report.

**Setting:** Unit of Assisted Reproduction, Gynecology and Obstetrics Institute, University of Belgrade.

**Patient(s):** A 30-year-old patient with 46,XY gonadal dysgenesis.

**Intervention(s):** Chromosomal analysis, diagnostic laparoscopy, IVF using donor oocytes, ET, and cesarean delivery.

**Main Outcome Measure(s):** Successful pregnancy and live birth.

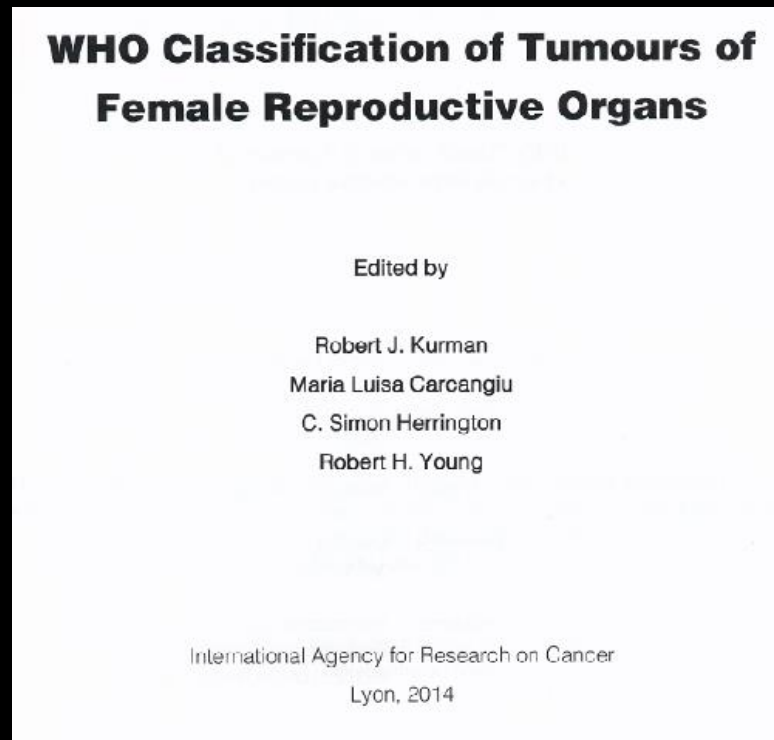
**Result(s):** Successful treatment, pregnancy, and delivery.

**Conclusion(s):** A patient with 46,XY gonadal dysgenesis in a donor oocyte program, can maintain a normal pregnancy and delivery. (Fertil Steril® 2011;95:1789.e1–e2. ©2011 by American Society for Reproductive Medicine.)

**Key Words:** Swyer syndrome, oocyte donation program, embryo transfer, pregnancy, cesarean section

• HRT + IVF

# TU - germinálne bb. + sex cord



## Germ cell - sex cord-stromal tumours

Gonadoblastoma, including gonadoblastoma

with malignant germ cell tumour

9073/1

Mixed germ cell-sex cord-

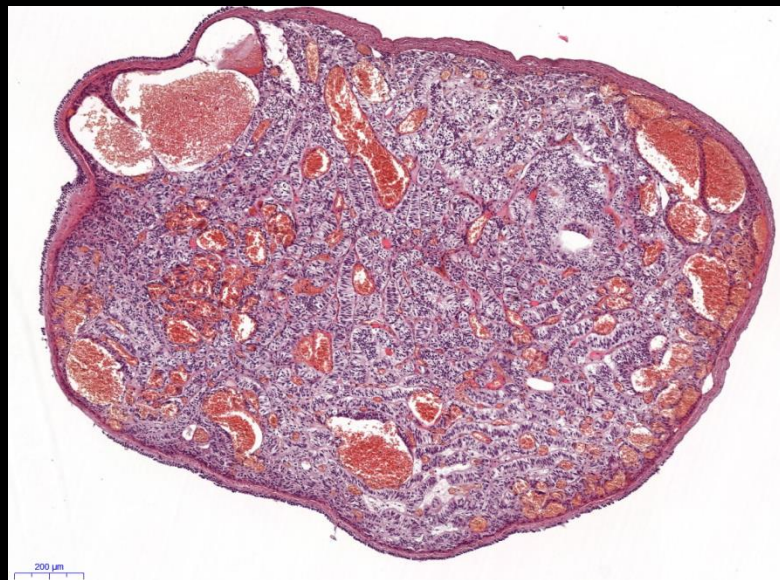
stromal tumour, unclassified

(bez gonadálnej dysgenézy) 8594/1\*

Talerman



# A čo tá Sertoli gulička?



*International Journal of Gynecological Pathology*  
18:91-93, Lippincott Williams & Wilkins, Philadelphia  
© 1999 International Society of Gynecological Pathologists

## Case Report

# Gonadoblastoma with Proliferation Resembling Sertoli Cell Tumor

Kouichi Nomura, M.D., Takaaki Matsui, M.D., and Shigeo Aizawa, M.D.

# Consensus Statement on Management of Intersex Disorders

Peter A. Lee, MD, PhD<sup>a,b</sup>, Christopher P. Houk, MD<sup>c</sup>, S. Faisal Ahmed, FRCPCH<sup>d</sup>, Ieuan A. Hughes, FMedSci, FRCPCH<sup>b,e</sup>, in collaboration with the participants in the International Consensus Conference on Intersex organized by the Lawson Wilkins Pediatric Endocrine Society and the European Society for Paediatric Endocrinology

January 28, 2019

*... terms such as “intersex,” “pseudohermaphroditism,” “hermaphroditism,” “sex reversal,” and gender-based diagnostic labels are particularly controversial. These terms are perceived as potentially pejorative by patients. We propose the term “disorders of sex development” (DSD)...*

TABLE 1 Proposed Revised Nomenclature

Previous	Proposed
Intersex	DSD
Male pseudohermaphrodite, undervirilization of an XY male, and undermasculinization of an XY male	46,XY DSD
Female pseudohermaphrodite, overvirilization of an XX female, and masculinization of an XX female	46,XX DSD
True hermaphrodite	Ovotesticular DSD
XX male or XX sex reversal	46,XX testicular DSD
XY sex reversal	46,XY complete gonadal dysgenesis



\*doc: "Sir, you've got a very rare disease"

\*pat: "how rare?"

\*doc: "you pick the name"



*d'akujem za pozornost*